

CASE REPORTS

Duodenal and Bile Duct Narrowing Due to Partial Annular Pancreas: A Rare Association

Suhas Udgirkar¹, Sanjay Chandnani¹, Vinay Zanwar², Ravindra Surude³, Qais Contarctor³, Pravin Rathi⁴

Abstract

Annular pancreas consists of a ring of pancreatic tissue partially or completely encircling the descending duodenum. It is an unusual congenital anomaly rarely detected in adult life. Gastric outlet obstruction is most common presentation mainly in 2nd or 3rd decades of life. We are reporting an unusual association of partial annular pancreas – a dilated biliary system due to distal common bile duct (CBD) stricture without features of pancreatitis or underlying malignancy which is rare and not reported previously. Our patient also had gastric outflow obstruction. This may be explained by the pancreatic tissue encircling the duodenum at the level where CBD joins the papilla causing dilated CBD and duodenal stenosis.

Introduction

Annular pancreas is a rare congenital anomaly consisting of a ring of pancreatic tissue partially or completely encircling the descending duodenum. The condition was first described by Tiedemann (1818) and labelled as “annular pancreas” by Ecker (1862).^{1,2} It usually affects neonates, but in the elderly it can mimic a wide range of clinical entities like peptic ulcer, pancreatitis, obstructive jaundice, etc. thereby making the diagnosis difficult. At present imaging modalities such as computerized tomography (CT), endoscopic retrograde cholangiopancreatography (ERCP), and magnetic resonance

cholangiopancreatography (MRCP) are used to arrive at a diagnosis. However, diagnosis is confirmed at surgery in 40% of the cases. This elderly female with annular pancreas presented with gastric outlet obstruction and distal CBD stricture without history of pancreatitis which is a rare presentation in adults.

Case Report

Fifty-four year old female presented with periumbilical colicky pain for the past 2 years. It would last for a few minutes and was associated with projectile nonbilious vomiting containing food eaten 1 to 2 hours before. There was no history of bowel rolling movement, abdominal distension or surgery in the past. Patient was anorexic and had lost approximately 6 kg weight in 6 months. She was pale and abdominal examination was normal. Routine investigations showed hemoglobin of 9.5 gm% with microcytic hypochromic anemia. Other laboratory parameters were normal. Abdominal sonography showed a dilated common bile duct (CBD), 11 mm and a distended stomach. There was liquid food residue and a hugely dilated stomach with smooth narrowing at the junction of the 2nd and 3rd part of duodenum on upper G. I. endoscopy (Figure 1). Scope could not be negotiated beyond this stricture.

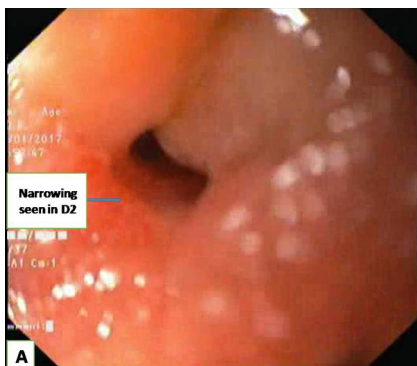


Fig. 1: Upper GI endoscopy showing smooth narrowing at D2 and D3 (duodenum) junction

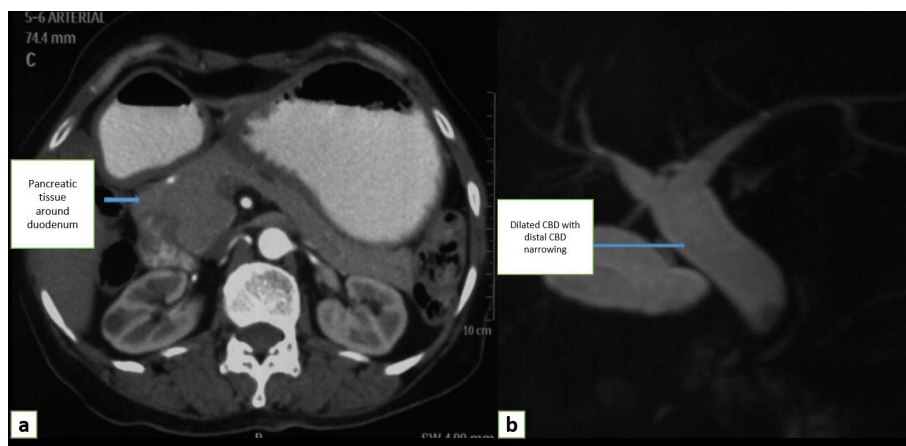


Fig. 2: (a) CT (computed tomography) abdomen showing pancreatic tissue around second part of Duodenum (arrow). (b) MRCP (magnetic resonance cholangiopancreatography) 3 dimensional reconstructed image showing dilated CBD with distal CBD stricture

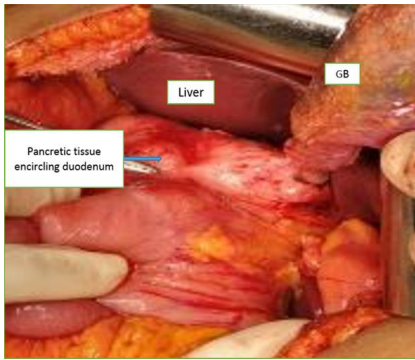


Fig. 3: Exploratory laparotomy image showing pancreatic tissue encircling duodenum

Abdominal CT scan confirmed that CBD was dilated at the hilar region with smooth narrowing of distal CBD and suspicious narrowing of duodenum by ventral pancreatic duct (Figure 2a). Rest of the pancreas was normal. Tumor markers, CEA and CA 19-9 were normal. Pancreatic tissue partially encircling the second part of duodenum suggestive of partial annular pancreas and a fusiformly dilated CBD with distal CBD narrowing were seen on MRCP (Figure 2b). At exploratory laparotomy a rim of pancreatic parenchyma was noted incompletely encircling the duodenum with compression of distal CBD (Figure 3). Patient underwent Roux-en-y-gastrojejunostomy and hepaticojejunostomy for distal CBD stricture. She is asymptomatic at 6 months follow-up. Distal CBD stricture in annular pancreas is associated with acute or chronic pancreatitis. However, this rare association without history of pancreatitis presenting in adults emphasizes the need to suspect external compression as a cause for distal CBD stricture.

Discussion

There are three types of pancreatic fusion anomalies - annular pancreas, pancreas divisum and partial annular pancreas - the latter being the rarest of all of them.

Five theories have been proposed to explain the pathogenesis of annular pancreas:³

1. Hypertrophy of both dorsal and ventral primordial
2. Persistence and enlargement of the left bud of the paired ventral primordial.
3. Fixation of the right bud of

the ventral primordial prior to rotation.

4. Adherence of the right ventral pancreatic bud to the duodenum.
5. Adherence of the tip of the left ventral angle to the duodenum.

The most commonly accepted theory explaining the development of annular pancreas is that of Lecco, who, in 1910, postulated that the tip of the ventral pancreatic bud fused abnormally to the duodenum⁴. This abnormal fusion leads to improper rotation of the ventral bud around the second portion of the duodenum during the fourth to ninth week of development. The result is a partial to complete ring of pancreatic tissue, which may include a major pancreatic duct, encircling the second portion of the duodenum. A single case was reported in 22,243 autopsies supporting the rarity of this condition.⁵ Uptill now 737 total cases and 160 adult cases have been reported in the literature. An incidence of 1.14% has been reported by Karasakiet al. based on institutional review of CT scans.⁶ Annular pancreas has bimodal age of presentation one in infancy (48%) and another in fourth decade of life (52%), though majority of the case reports are from infant age groups.^{7,9} Annular pancreas is frequently associated with other congenital anomalies in adults like malrotation, duodenal web and Schatzki ring. Long Cheng et al. reported a case of annular pancreas associated pancreaticobiliary maljunction presenting with obstructed biliary system in an adult patient.⁸ Incidence of gastric outlet obstruction was similar in partial or complete annular pancreas. Zyromskiet al reviewed the literature and reported that 75% had abdominal pain as the primary complaint, 24% presented with symptoms of gastric outlet obstruction, 11% had jaundice and 22% had acute pancreatitis.⁹ Pancreatitis is possibly related to the high coincidence of pancreas divisum (29%), with variable duration of symptoms from a few months to several years. Patient may have obstructed biliary system due to malignancy or associated chronic pancreatitis. Our patient had obstructed biliary system without obstructive jaundice and with normal underlying pancreas which may be explained by possible compression by pancreatic tissue encircling at a level where the CBD

joins the ampulla. Previous case reports of acute pancreatitis or malignancy causing obstructive jaundice have been reported.¹⁰ Association of distal CBD stricture with normal liver function tests and normal underlying pancreas has not been reported previously emphasizing this rare association in the present case.

The diagnosis of annular pancreas can be made preoperatively using numerous radiologic and endoscopic studies. However, in over 40% of cases, the diagnosis is only made at laparotomy.¹¹ In CT and magnetic resonance imaging (MRI), a ring of pancreatic tissue is seen surrounding the descending duodenum, in continuity with the pancreatic head and MRCP or ERCP can identify the annular pancreatic duct encircling and extending to the right side of the duodenum.^{12,13}

Endoscopic ultrasonography can also be useful in non-obstructive forms.¹⁴ The treatment of symptomatic, obstructing annular pancreas has classically been surgical. The preferred treatment is a bypass operation such as gastro- or duodenojejunostomy, but some cases were treated by division of the annulus with transverse duodenoplasty, duodenoduodenostomy, or Whipple's procedure depending on the case and the intra-operative findings.¹⁵ Thus annular pancreas though common in children should be suspected in adults with gastric outlet obstruction and may have distal CBD stricture probably due to external compression which is a rare association.

References

1. Tiedemann F. Uber die Verschiedenheiten des Ausfuhrungsganges der Bauchspeicheldruse bei den Menschen und den Säugetieren. *Dtsch Arch Physiol* 1818; 4:403.
2. Ecker AV. Bildungsfehler des Pankreas und des Herzens. *Z Rat Med Leipz* 1862; 14:354-6.
3. Langman J. Medical Embryology. 4th Edition. Baltimore. *Williams and Wilkins*, 1981; 220-223.
4. Lecco TM. Zur morphologie des pankreas annulare. *Sitzungsb Wien Akad Wiss*. 1910;119:391-406. Lecco TM. Zur morphologie des pankreas annulare. *Sitzungsb Akad Wissensch* 1910; 119:391-406.
5. Vasconcelos E, Sadek HM. Pancreas annular produzindo. *Rev Bras Gastroenterol* 1949; 1:535-551.
6. Karasaki H, Mizukami Y, Ishizaki A, Goto J, Yoshikawa D, Kino S, Tokusashi Y, Miyokawa N, Yamada T, Kono T, Kasai S. Portal annular pancreas, a notable pancreatic malformation: frequency, morphology, and implications for pancreatic surgery. *Surgery* 2009; 146:515-8.
7. Ravitch MM. The pancreas in infants and children. *Surgical Clinics of North America* 1975; 55:377-85.
8. Cheng L, Tian F, Zhao T, Pang Y, Luo Z, Ren J. Annular

- pancreas concurrent with pancreaticobiliary maljunction presented with symptoms until adult age: case report with comparative data on pediatric cases. *BMC Gastroenterology* 2013; 13:153.
9. Zyromski NJ, Sandoval JA, Pitt HA, Ladd AP, Fogel EL, Mattar WE, Sandrasegaran K, Amrhein DW, Rescorla FJ, Howard TJ, Lillemoie KD. Annular pancreas: dramatic differences between children and adults. *Journal of the American College of Surgeons* 2008; 206:1019-25.
 10. Yasui A, Nimura Y, Kondou S, Kamiya J. Duodenal obstruction due to annular pancreas associated with pancreatic head carcinoma. *Hepato-gastroenterology* 1995; 42:1017.
 11. Rizzo RJ, Szucs RA, Turner MA. Congenital abnormalities of the pancreas and biliary tree in adults. *Radiographics* 1995; 15:49-68.
 12. Nijs EL, Callahan MJ. Congenital and developmental pancreatic anomalies: ultrasound, computed tomography, and magnetic resonance imaging features. In *Seminars in Ultrasound, CT and MRI* 2007 Oct 31 (Vol. 28, No. 5, pp. 395-401). WB Saunders.
 13. Türkvatan A, Erden A, Türkoğlu MA, Yener Ö. Congenital variants and anomalies of the pancreas and pancreatic duct: imaging by magnetic resonance cholangiopancreatography and multidetector computed tomography. *Korean Journal of Radiology* 2013; 14:905-13.
 14. Kandpal H, Bhatia V, Garg P, Sharma R. Annular pancreas in an adult patient: diagnosis with endoscopic ultrasonography and magnetic resonance cholangiopancreatography. *Singapore Med J* 2009; 50:e29-31.
 15. Johnston DW. Annular pancreas: a new classification and clinical observations. *Canadian journal of surgery. Journal Canadien de Chirurgie* 1978; 21:241-4.