

## PICTORIAL CME

# Familial Hypercholesterolemia with Different types of Xanthomas

Rajashree Khot<sup>1</sup>, Keshav Nagpure<sup>2</sup>

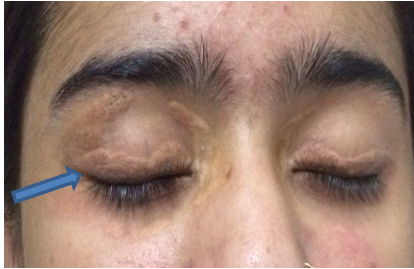

Fig. 1: Xanthoma Palpebrum

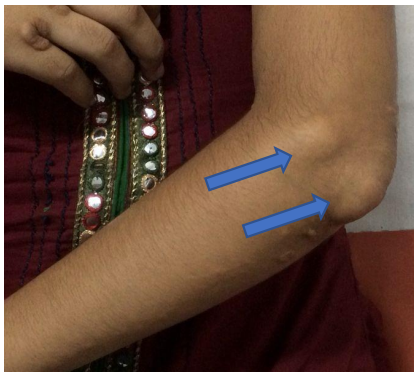

Fig. 2: Tuberos Xanthomas

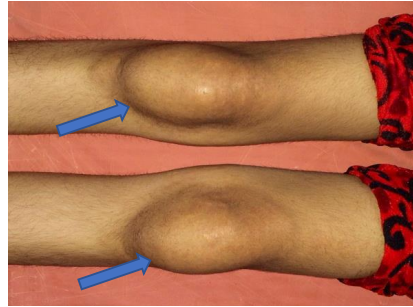


Fig. 3: Tendinous Xanthomas

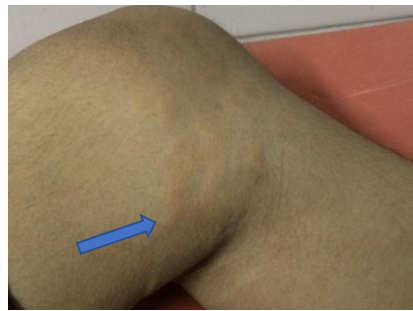

Fig. 4: Planar Xanthomas

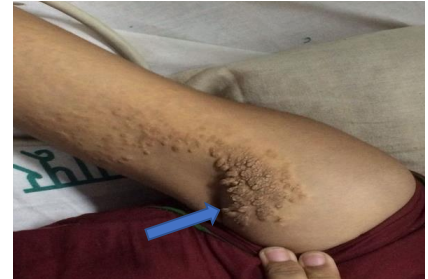

Fig. 5: Eruptive Xanthomas

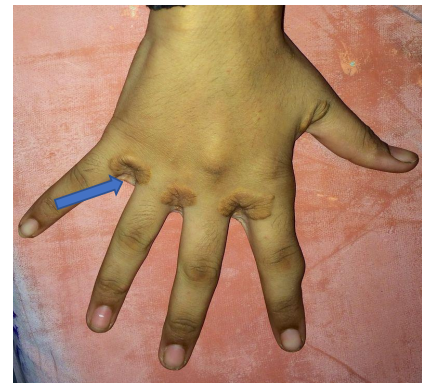

Fig. 6: Intertriginous Xanthomas

## Case Summary

A 15-year-old girl residing in a remote village came with a history of multiple skin lesions of variable morphology ranging from macules to nodules over various parts of the body since childhood. They were painless and growing in number slowly. Patient was more concerned about the cosmetic effect of the lesions. On examination patient had all different types of Xanthomas which have been described with familial hypercholesterolemia. She had Xanthelasma Palpebrum over the eyes (Figure 1), Tuberos Xanthoma over the elbow (Figure 2), Tendinous Xanthomas over the knee and Achilles tendon (Figure 3), Diffuse planar Xanthomas over thighs (Figure

4), Eruptive verrucous Xanthomas in the axillae, forearms, legs (Figure 5) and Intertriginous Xanthomas on hand (Figure 6). Her mother only had palpebral Xanthelasma. Her Father and elder sister were normal. Her lipid profile revealed elevated Serum Cholesterol of 291 mg/dl, elevated Serum LDL of 241 mg/dl, low HDL of 38 mg/dl and normal Triglyceride levels of 64 mg/dl and normal VLDL levels of 30 mg/dl. Her mother also had marginally elevated levels of Serum cholesterol and LDL. Her 2-D Echo revealed restricted movement of anterior mitral

leaflet and mild mitral regurgitation. Patient's parents did not give consent for coronary angiography. There were no plaques in the carotid artery and carotid intima media thickness was also normal. According to Simone Broom criteria patient was diagnosed to have Familial hypercholesterolemia. She was started on Tab Atorvastatin with ezetimibe but on follow up after 6 weeks her lipid profile was unaltered.

<sup>1</sup>Associate Professor, <sup>2</sup>Assistant Professor, Department of Medicine, Indira Gandhi Government Medical College, Nagpur, Maharashtra

Received: 26.05.2017; Accepted: 21.12.2017