

# Overlap Syndrome : Autoimmune Hepatitis with Primary Biliary Cirrhosis

S Arulprakash\*, Anand D Sasi\*, Murali R Bala\*\*, T Pugazhendhi\*\*\*, S Jeevan Kumar\*\*\*

## Abstract

“Overlap syndrome” is used to describe variant forms of autoimmune hepatitis (AIH) which present with characteristics of AIH and primary biliary cirrhosis (PBC) or primary sclerosing cholangitis (PSC). Patients with overlap syndromes present with both hepatitic and cholestatic serum liver tests and have histological features of AIH and PBC or PSC. AIH-PBC is the most common form of overlap syndrome, affecting almost 10% of adults with AIH or PBC. Transitions from PBC to AIH-PBC overlap syndrome have also been reported. Overlap syndromes show a progressive course without treatment, and therapy is empiric. Ursodeoxycholic acid is usually combined with immunosuppressive therapy but end-stage disease requires liver transplantation. We report a case of AIH/PBC overlap with relevant discussion of literature.

## Introduction

Autoimmune hepatitis (AIH), primary biliary cirrhosis (PBC) and primary sclerosing cholangitis (PSC) are the three major immune disorders of the liver. The coexistence of primary biliary cirrhosis (PBC) and autoimmune hepatitis (AIH) occurring simultaneously has been called “overlap syndrome”. Overlap syndromes should always be considered once an autoimmune liver disease has been diagnosed.<sup>1</sup> The diagnostic criteria for this variant form of PBC have not been standardized. A hepatic biochemical profile typically coexists with cholestatic laboratory changes.<sup>2</sup> Although autoantibodies are detected in up to 65% of patients with chronic hepatitis C, it's inappropriate to use the term overlap syndrome for coexistence of AIH and other chronic liver diseases.

## Case Report

A 44-year-old woman was admitted to our hospital with abdomen distension, jaundice, edema legs of 2 months duration. She also had 2 episodes of hematemesis and was passing pale stools 2 weeks prior to admission. There was a history of jaundice 1 year back, details not available with the patient. She reported fatigue and slight pruritus, but was otherwise in good health

in the intervening period. She denied any intake of hepatotoxic drugs. Clinically she was deeply icteric with pedal edema and had abdomen distension with free fluid. Spleen was palpable 5 cm below left costal margin. She was afebrile with scratch marks over trunk and extremities. Clinical diagnosis of chronic liver disease with decompensation was considered and evaluated for etiology.

Investigations: Hemoglobin 9.7 g/dL; prothrombin time 16/12s, bilirubin 12.8 mg/dL (direct 9.6), serum AST 312 IU/L, ALT 260 IU/L, alkaline phosphatase 389 IU/L, serum proteins 6.2 g/dL (albumin 2.8); blood urea 33 mg/dL, serum creatinine 0.7 mg/dL. Serum HIV, HBsAg, IgM anti-HAV and HCV antibody were negative. Ultrasonography showed nodular shrunken liver with splenomegaly and ascites. Ascitic fluid analysis was low protein high SAAG, suggesting portal hypertension. Anti-nuclear antibody (ANA) 1:100 dilution, Anti LKM anti body (1:100) were positive. Anti-smooth muscle antibody (SMA) was negative. Anti-mitochondrial (M2 antigen) antibody (AMA) was positive. She had Grade II esophageal varices and mild portal hypertensive gastropathy on upper GI endoscopy. Liver biopsy was done which revealed lymphocytic infiltrates, bile duct loss with proliferation and hepatocytes showed feathery degeneration, intrahepatic cholestasis and minimal regeneration. Biopsy was suggestive of auto immune hepatitis with florid bile duct lesion (Fig. 1) AIH-PBC overlap syndrome was diagnosed using the criteria mentioned below and was started on oral ursodeoxycholic acid (UDCA; 15 mg/Kg/day). Hepatic decompensation was managed appropriately. There was some improvement in liver biochemistry after UDCA (bilirubin 7.7 mg/dL (direct 3.8), serum AST 118 IU/L, ALT 90 IU/L, alkaline phosphatase 210 IU/L). We restrained from starting steroids as she had decompensated liver disease. At the last follow-up, the patient reported an improved general condition, and fatigue and pruritus disappeared.

## Discussion

PBC and AIH are the most frequent autoimmune liver disease with a female preponderance. Clinical presentation depends on predominant component of disease. Patients with overlap syndromes usually present with nonspecific symptoms, including fatigue, arthralgia, myalgia, jaundice and pale stools. Serum liver tests typically show a hepatitic pattern in AIH and a cholestatic pattern with marked elevation of AP and  $\gamma$ -GT, but mild elevation of serum transaminases in PBC. While serum IgG is the predominant immunoglobulin elevated in AIH, serum IgM is elevated in most patients with PBC. Patients presenting with

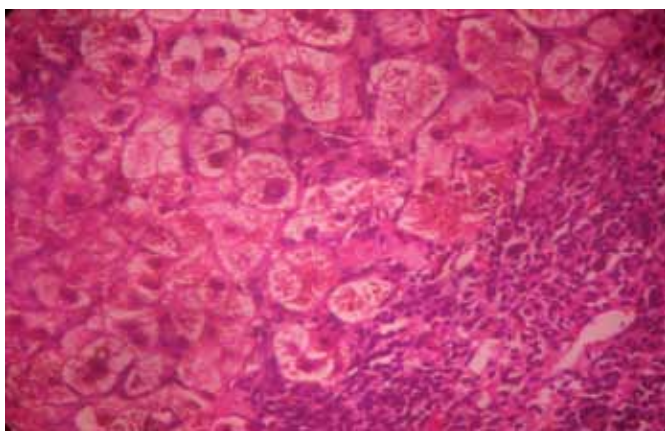


Fig. 1 : Liver biopsy showing lymphocytic infiltrates, bile duct loss with proliferation and hepatocytes showed feathery degeneration, intrahepatic cholestasis and minimal regeneration. Features suggestive of auto immune hepatitis with florid bile duct lesion.

\*Resident, Medical Gastroenterology, \*\*Assistant Professor Medical Gastroenterology, \*\*\*Professor Medical Gastroenterology, Department of Digestive Health and Diseases, (Government Peripheral Hospital), Kilpauk Medical College Hospital, Chennai 600 102.  
Received: 13.04.2009; Accepted: 04.06.2009

clinical, biochemical, serological and histological features of both these diseases have been reported and described as "overlap syndrome". Although there is no uniformly accepted criteria for diagnosis,<sup>3</sup> the diagnostic criteria defined by Chazouillères et al. are based on the presence of at least two of the following three types of features characteristic of each disease: biochemical (ALP levels at least twofold / GGT > at least five fold and ALT levels at least fivefold the upper normal PBC and AIH values, respectively); immunologic (presence of AMA in the case of BPC, and serum IgG levels at least twofold the upper normal values or the presence of ASMA in that of AIH); and histologic (florid bile duct lesions in the case of PBC and interface hepatitis in that of AIH). In the present case, the patient satisfied the aforementioned diagnostic criteria.<sup>4</sup> Autoantibodies are generally believed as a hallmark for the diagnosis of AIH. Serum ANA in patients with PBC are not a marker of AIH-PBC overlap syndrome, but often found in PBC patients without further signs of AIH. ANA with a specific immunofluorescence pattern of multiple nuclear dots directed against Sp100 or Coilin p80 are rather specific although less sensitive for PBC. Patients with AIH-PBC overlap syndrome show a predominant HLA type B8, DR3, or DR4 similar to AIH and a good response to corticosteroid treatment.<sup>5</sup> The presence of soluble liver antigen (SLA) autoantibodies was found to be a marker of AIH-PBC overlap syndrome with a good response to immunosuppressive therapy. The time interval between the diagnosis of PBC and the diagnosis of AIH varied from 6 months to 13 years.

Recommendations for the treatment of PBC–AIH overlap syndrome have not yet been standardized owing to the low prevalence of this autoimmune liver disease. Because no randomized controlled therapeutic trials have been carried out so far, recommendations for treating PBC–AIH overlap syndrome are usually based on the methods used to treat the two main autoimmune liver diseases separately. It's appropriate to start treatment with UDCA (13-15 mg/kg daily). However, if this therapy does not induce an adequate biochemical response in an appropriate time span (e.g. 3 months)<sup>6</sup> or in patients with predominantly hepatic serum liver tests, a corticosteroid should be added. Prednisone has been used at an initial dose of 0.5 mg/kg daily and should be progressively tapered once ALT levels show a response. The role of other immunosuppressants, (azathioprine) in the long-term management of patients with AIH-PBC overlap syndrome is unclear, but it's an

alternative to corticosteroids for long-term immunosuppressive therapy. Budesonide and cyclosporine A has also been used in patients with AIH-PBC overlap syndrome with success.<sup>7</sup> Liver transplantation is regarded as the treatment of choice for end-stage disease. Recent studies have shown AIH-PBC overlap syndrome might have worse clinical outcomes compared to patients with PBC alone.<sup>7</sup>

## Conclusion

AIH-PBC overlap syndrome is the commonest of all overlap syndromes and has to be considered while diagnosing autoimmune hepatitis. The diagnostic criteria for this variant form of PBC have not been standardized, nor has its frequency and appropriate treatment strategy been established. As of now treatment of this condition is with UDCA, immunosuppressants and liver transplantation.

## References

1. Czaja AJ. The variant forms of autoimmune hepatitis. *Ann Intern Med* 1996;125:588-598.
2. Beuers U. Hepatic overlap syndromes. *J Hepatol* 2005;42 Suppl: S93-S99.
3. Duclos-Vallee JC, Hadengue A, Ganne-Carrie N, Robin E, Degott C, Erlinger S. Primary biliary cirrhosis-autoimmune hepatitis overlap syndrome. Corticoreistance and effective treatment by cyclosporine A. *Dig Dis Sci* 1995;40:1069-1073.
4. Chazouillères O, Wendum D, Serfaty L, Montembault S, Rosmorduc O, Poupon R. Primary biliary cirrhosis autoimmune hepatitis overlap syndrome: clinical features and response to therapy. *Hepatology* 1998;28:296-301.
5. Gerken G, Dienes HP. Characterization of the overlap syndrome of primary biliary cirrhosis (PBC) and autoimmune hepatitis: evidence for it being a hepatic form of PBC in genetically susceptible individuals. *Hepatology* 1999;29:1078-1084.
6. Heathcote EJ. Overlap syndromes. In: Bircher JBJ, McIntyre N, Rizzeto M, Rodès J, eds. *Oxford Textbook of Clinical Hepatology*, Vol. 2. Oxford: Oxford University Press, 1999;1135–40.
7. Overlap syndromes among autoimmune liver diseases. Pietro Invernizzi, MD; Ian R Mackay, MD, *World J Gastroenterol* 2008;14:3368-3373.