

## PICTORIAL CME

## Cutaneous Lymphangiectasia of Genitalia: A Rare Occurrence

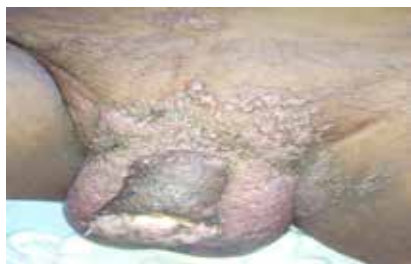Savita Arya<sup>1</sup>, Asha Nyati<sup>2</sup>, Moti Lal Bunkar<sup>3</sup>

Fig. 1: Genitalia and pubic region

## Case History

A 70 years old male presented with complaints of multiple raised lesions over scrotum and penis since five years. On local genital examination, there were single and grouped, non-tender, non-pruritic, translucent and papulovesicular lesions involving scrotum, supra pubic region and thigh. Penile lesion was tender, ulcerated and nodular, more over prepuce and glans penis with no regional lymphadenopathy (Figure 1). The routine blood investigations, ultrasonography of the abdomen and pelvic organs revealed no abnormality. Screening tests for human immunodeficiency virus, VDRL, hepatitis B virus, chlamydia and filariasis serology were also non-reactive. Biopsy revealed thin-walled and ectatic lymphatic channels in the superficial dermis. The dermal papillae and the dermis showed proliferating, congested capillary

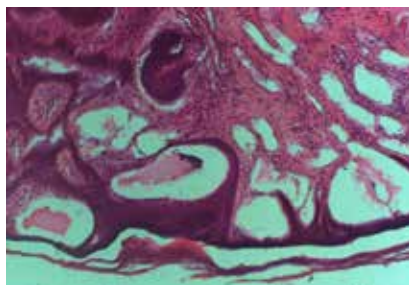


Fig. 2: Biopsy suggestive of lymphangiectasia. (H and E, 40 X)

sized blood vessels, melanophages and diffuse as well as perivascular mild inflammatory infiltrate suggestive of lymphangiectasia (Figure 2b, H and E, 40 X). Patient advised for ablative treatment like but he refused due to social reason and later lost to follow up.

## Discussion

Cutaneous lymphangiectasias (CL) or acquired lymphangioma is a lymphatic malformation, mostly congenital, whereas the acquired CL occurs due to obstruction of deeper lymphatic vessels secondary to other etiology.<sup>1</sup> It involves dermal and subcutaneous lymphatic channels and characterized by presence of a circumscribed eruption of thin-walled, translucent vesicles and

ranges from clear, fluid filled blisters to smooth, flesh-coloured nodules, sometime coexisting lymph oedema. The lymphatic vessels of the superficial dermal plexus drain a fixed area of skin through the vertical collecting lymphatics to the deep plexus. The damage to deep lymphatic vessels leads to back-pressure and dermal backflow, with subsequent dilatation of the upper dermal lymphatics.<sup>2</sup> It has to be differentiated from herpes genitalis, genital warts or molluscum contagiosum. Mostly CL is asymptomatic but pruritus, burning or painful lesion and sometime foul smelling viscous discharge may also occur. The diagnosis is mainly clinical, aided by histopathological finding of dilated lymphatics in the dermis. Treatment should be directed towards the etiology and aimed at reduction of underlying lymph edema and control of infection.

## References

1. Arya S, Nyati A, Bunkar M, Takhar RP, Mirdha S. Cutaneous lymphangiectasia of the vulva secondary to pulmonary tuberculosis: a case report. *Int J Res Dermatol* 2015; 1:14-6.
2. Singh N, Kumari R, Thappa DM. Vulval lymphangiectasia secondary to tubercular lymphadenitis. *Indian J Sex Transm Dis* 2007; 28:38-39.

<sup>1</sup>Final Year Resident, <sup>2</sup>Assistant Professor, Department of Skin and VD, <sup>3</sup>Senior Resident, Department of Respiratory Medicine, Government Medical College, Kota, Rajasthan  
Received: 05.15.2016; Accepted: 12.06.2017